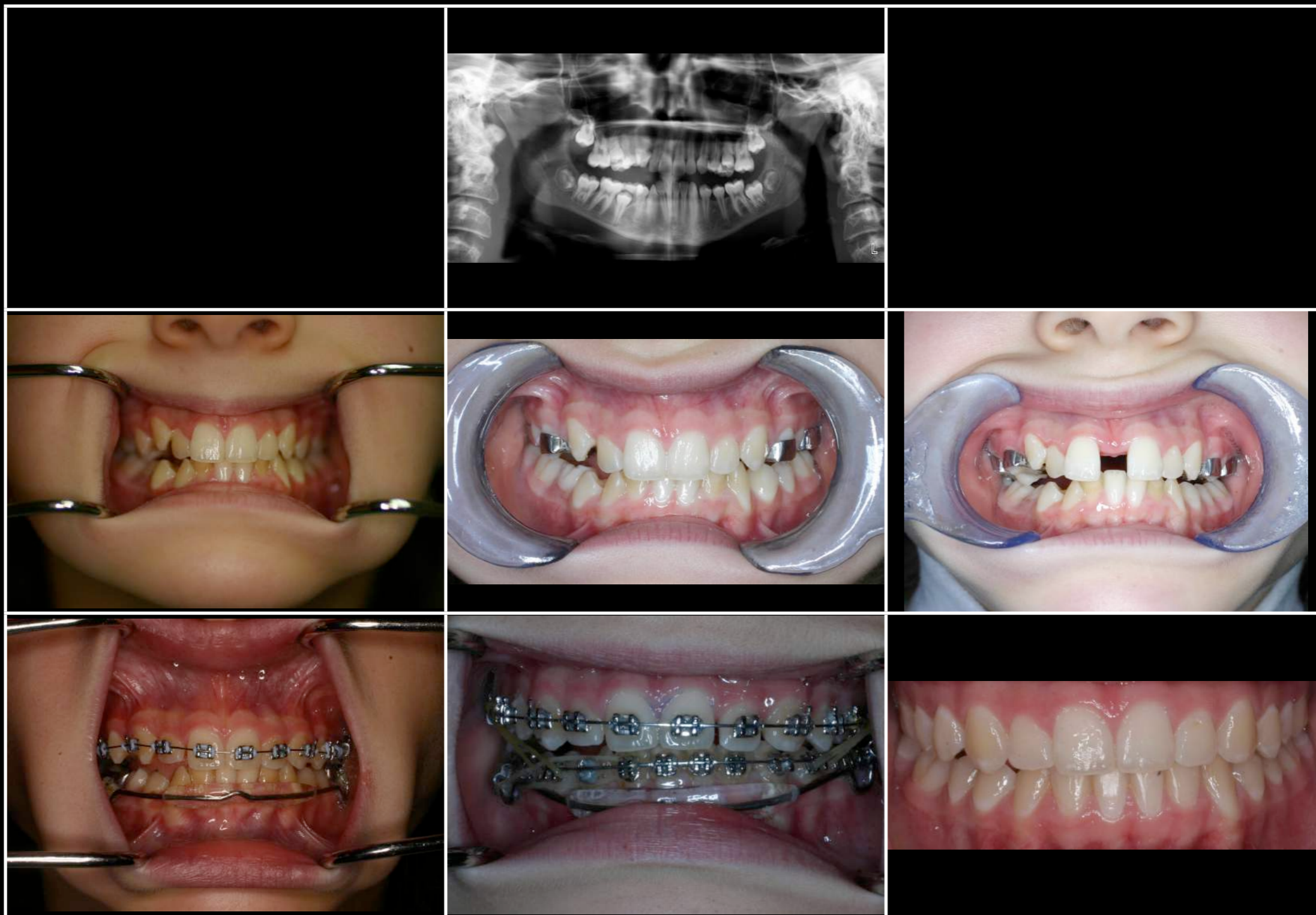
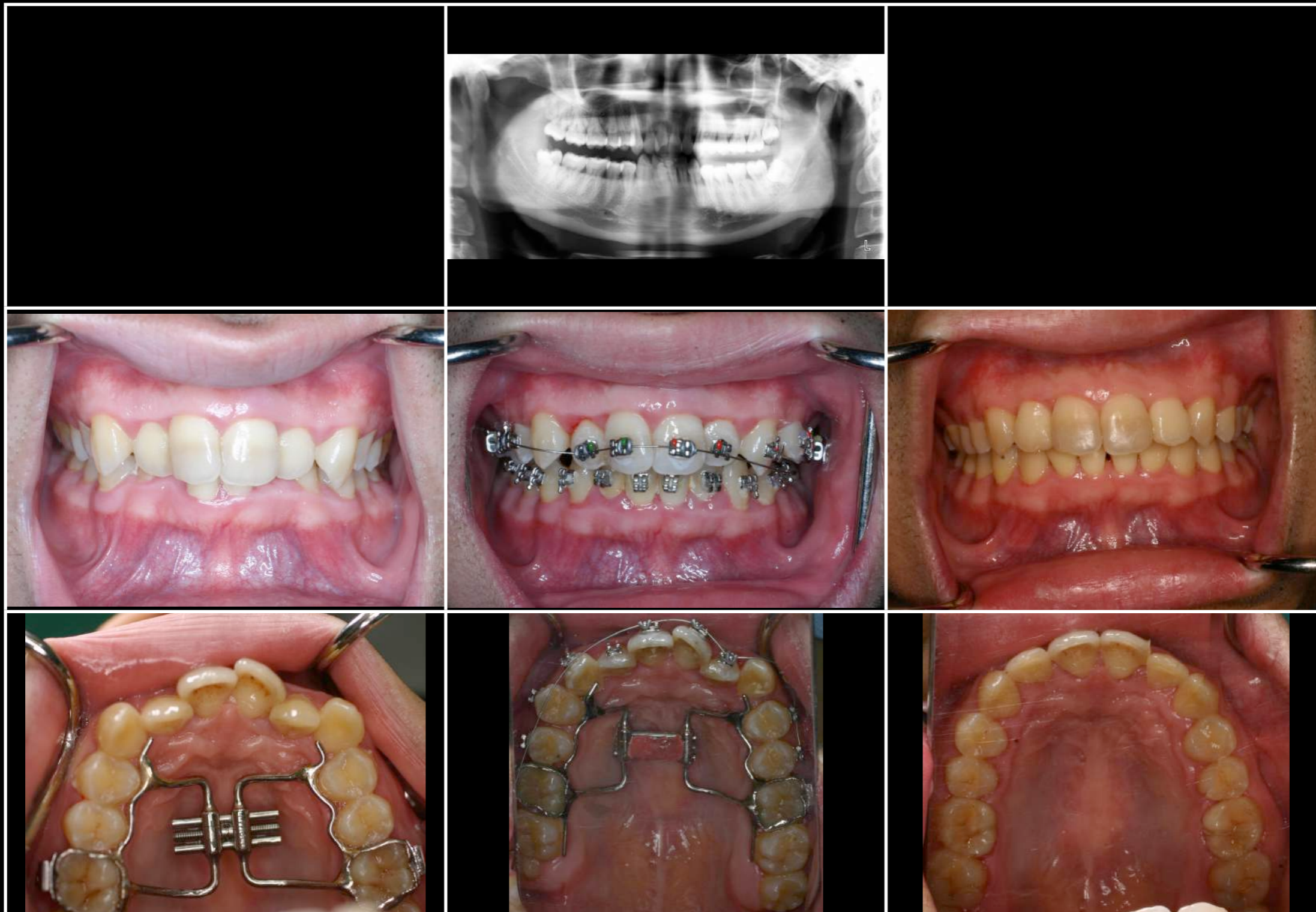


# CASI CLINICI ORTODONZIA

# Caso Clinico 1



# Caso Clinico 2



# Caso Clinico 3 : disodontiasi 47

